

# A rare complication of percutaneous coronary artery intervention

## INTRODUCTION

Coronary angiogram and PCI are common procedures performed daily in cardiac centres. Vascular complications are well known to occur during and after these procedures. We would like to report a rare postprocedural complication of percutaneous coronary artery intervention.

## CASE REPORT

A 40-year-old man with underlying type 2 diabetes mellitus, hypertension and gouty arthritis presented to our hospital in October 2008 with an acute inferior myocardial infarction. He was successfully treated with intravenous thrombolytics and was discharged. His outpatient exercise stress test was strongly positive, so arrangements were made for an elective coronary angiogram.

The coronary angiogram revealed two-vessel disease—distal RCA 70% stenosis and proximal LAD 80% stenosis. The left main stem and the circumflex artery were normal. Percutaneous coronary angioplasty and stenting (PCI) to the proximal LAD were performed. Besides raised blood pressure measurements (systolic 200–180, diastolic 100–110), which were treated with intravenous calcium antagonist and nitrates, the procedure was uncomplicated and successful. A renal angiogram revealed no abnormalities. The patient remained asymptomatic throughout the procedure. The total procedure time and intravenous contrast media usage (Ultravist-370) was 90 min and 200 ml respectively.

During routine post-PCI review in the ward, the patient complained of giddiness, headache and bilateral blurring of

vision. There were no other associated neurological symptoms. A complete neurological examination was performed, which revealed no abnormalities except severely reduced visual acuity bilaterally (perception only to light). An ophthalmological examination and test confirmed the presence of bilateral cortical blindness. His blood pressure in the ward was noted to be high (systolic 170–180, diastolic 100–120). A bedside blood glucose test revealed normal levels.

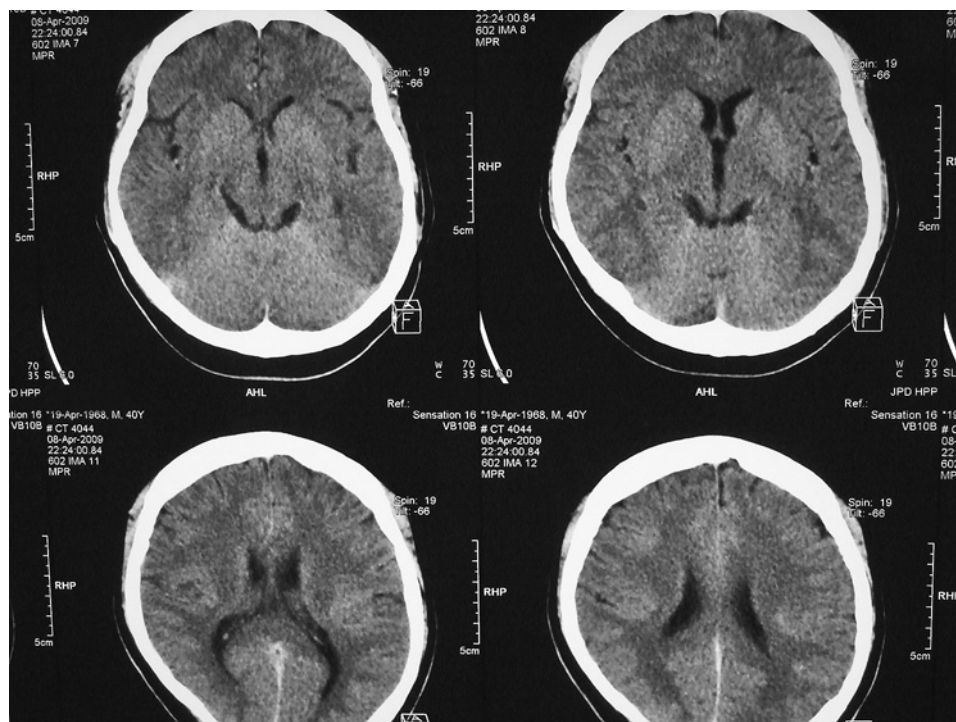
The patient's blood pressure was controlled with intravenous nitrates and oral antihypertensive agents. Intravenous normal saline (0.9N/S%) hydration was also commenced. Urgent non-contrasted CT brain revealed hyperdensity along the interhemispheric fissure, extending along the tentorium, suggestive of subarachnoid haemorrhage (figure 1). Arrangements were made for an urgent MRI of the brain to further elucidate the cause of the intracranial bleed.

Surprisingly, the MRI brain was reported as normal (figure 2). The patient was observed in the ward and regained complete recovery of his vision and symptoms within 24 h post-PCI. The patient was diagnosed as having contrast-induced transient cortical blindness. Upon control of his blood pressure, the patient was discharged. He remained well and asymptomatic on review in the outpatient clinic 6 weeks later.

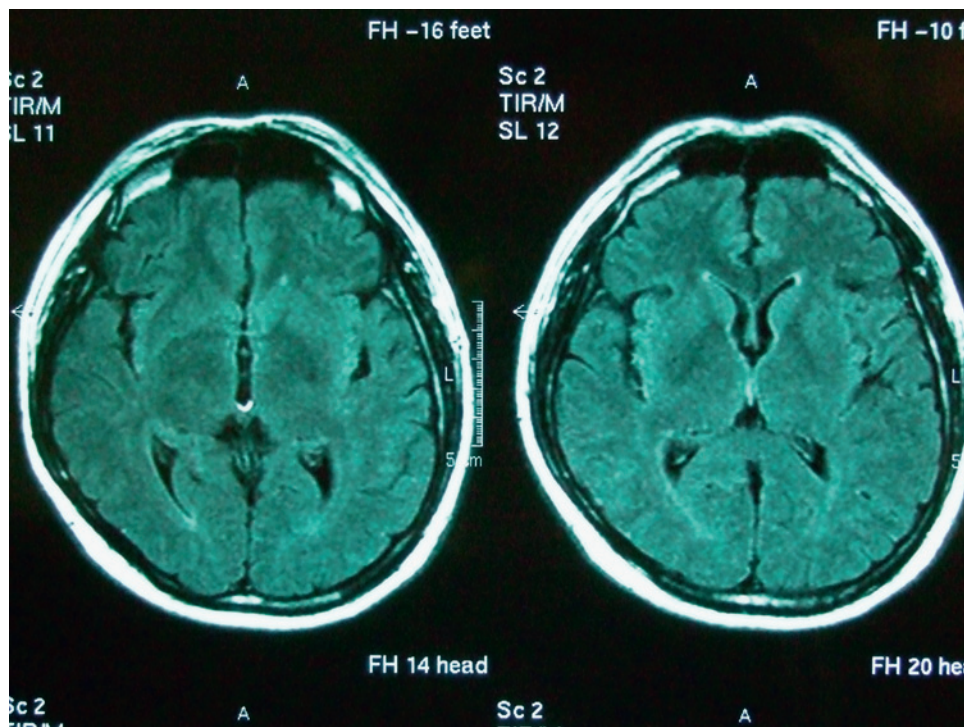
## DISCUSSION

Percutaneous coronary artery angioplasty and intervention (PCI) are common procedures performed in major cardiac centres. Vascular and bleeding-related problems (<1%)<sup>1</sup> stroke (<0.07%)<sup>2</sup> and allergic reaction to iodinated contrast agent (1%) are well-documented complications of this procedure. To date, fewer than 20 documented cases of transient cortical blindness have been reported worldwide.<sup>3–9</sup>

A common feature of this complication among most of the reported cases including ours were the presence of high blood pressure recorded during and after the procedure.<sup>8–9</sup> Patients



**Figure 1** Non-contrast CT brain revealed hyperdensity along the interhemispheric fissure, extending along the tentorium, suggestive of subarachnoid haemorrhages.



**Figure 2** Normal MRI brain in contrast to CT brain findings in the same patient.

usually develop acute visual acuity disturbances during this period. In view of the rare nature of this complication, other possible causes of cortical blindness such as intracerebral haemorrhage, thromboembolic stroke and intracranial vascular dissection need to be ruled out urgently.

Non-contrast CT brain findings suggestive of a subarachnoid bleed in this patient were most probably due to enhancement of contrast in the occipital region, which was also documented in other cases.<sup>4–6 8 9</sup> The underlying pathophysiology for this CT brain findings was postulated to be due to direct contrast slippage into occipital cortex following the breakdown in the blood–brain barrier.<sup>10</sup> This is further aggravated by the increased permeability of blood–brain barrier due to uncontrolled blood pressure and the supine position of the patient during and postprocedure. Uncontrolled hypertension was also reported to cause reversible oedema secondary to disturbance of autoregulation of posterior cerebral vessels.<sup>8 9 11</sup>

The role of contrast tonicity and volume is still unclear. Iopromide is an iso-osmolar non-ionic contrast agent. Similar contrast was used in one of the reported cases.<sup>8</sup> Although the incidence of cortical blindness is higher with hyperosmolar iodinated contrast agents,<sup>12 13</sup> this complication can also occur with newer low-osmolar or iso-osmolar nonionic contrast agents. This complication has also been described in the product information of contrast agents as a rare undesirable side effect with an incidence of <1/1000.

Vision impairment usually returns to normal after the contrast media has been excreted naturally through the urinary tract. Normal duration of excretion may range between 15 min and 3 weeks (average 72 h). Almost all patients in the reported cases had complete recovery of vision within 24 h post-procedure. One patient had only partial recovery of his vision, and further investigation with the CT scan and MRI brain confirmed the presence occipital infarction.<sup>11</sup> To date, there have also been no reports regarding patients who experience repeated

transient cortical blindness due to contrast use for coronary angiography or other procedures.

We postulate that apart from idiosyncratic neurotoxicity secondary to contrast affecting the occipital region,<sup>4</sup> prolonged exposure and high volume of contrast could also induce changes at the neuronal level that may cause apoptosis leading to documented infarction in the affected area. If this postulation is true, perhaps good control of blood pressure, hydration with intravenous saline, minimal amount of contrast and shorter procedural time could prevent possible serious reaction that may lead to irreversible damage to the affected neuron.

## CONCLUSION

Several cases of contrast-induced transient cortical blindness are now well reported. We need to recognise this rare entity in our clinical practice of contrast-related procedures. Nonetheless, important differential diagnoses need to be ruled out by CT and MRI brain. Although vision loss is transient with complete recovery in most of the cases, irreversible injury could occur if cortical damage is severe or prolonged. Good control of blood pressure, hydration, shorter procedural time and minimal usage of contrast could prevent irreversible damage to the cortical neurons.

**Wai Sun Choo, Badusha Abdul Kareem Barakath, Boon Keat Tan, Omar Ismail**

waisun76@yahoo.com

**Competing interests** None.

**Patient consent** Obtained.

**Ethics approval** Ethics approval was provided by the local hospital committee.

**Provenance and peer review** Not commissioned; externally peer reviewed.

*Heart Asia* 2010;131–132. doi:10.1136/ha.2009.001222

## REFERENCES

1. **Noto TJ**, Johnson LW, Krone R. Cardiac catheterization 1990: a report of the registry of Society for Cardiac Angiography and Interventions. *Cathet Cardiovasc Diagn* 1991;**24**:75.
2. **Johnson LW**. Coronary angiography 1984–1987: a report of the registry of Society for Cardiac Angiography and Interventions, I: results and complications. *Cathet Cardiovasc Diagn* 1989;**17**:5.
3. **Fischer-Williams M**, Gottschalk PG, Browell JN. Transient cortical blindness: an unusual complication of coronary angiography. *Neurology* 1970;**20**:353–5.
4. **Kinn RM**, Breisblatt WM. Cortical blindness after coronary angiography: a rare but reversible complication. *Cathet Cardiovasc Diagn* 1991;**22**:177–9.
5. **Parry R**, Rees JR, Wilde P. Transient cortical blindness after coronary angiography. *Br Heart J* 1993 **70**:563–4.
6. **Sticherling C**, Berkefeld J, Auch-Schweik W, *et al*. Transient bilateral cortical blindness after coronary angiography. *Lancet* 1998;**351**:570.
7. **Kwok BWK**, Lim TT. Cortical blindness following coronary angiography. *Singapore Med J* 2000;**41**:604–5.
8. **Lim KK**, Radford D. Cortical blindness related to coronary angiography and graft study. *Med J Aust* 2002;**177**:43–4.
9. **Mehmet Y**, Hakan O, Kinay O, *et al*. Transient cortical blindness after cardiac catheterization with lobitridol. *Tex Heart Inst J* 2007;**34**:373–5.
10. **Lantos G**. Cortical blindness due to osmotic disruption of the blood–brain barrier by angiographic contrast material: CT and MRI studies. *Neurology* 1989;**39**:567–71.
11. **Ravi S**, Sandeep S, Vinay B. an uncommon complication after a common procedure. *J Invasive Cardiol* 2008;**20**:E301–3.
12. **Rama BN**, Pagano TV, Delcore M, *et al*. Cortical blindness after cardiac catheterisation: effect of re-challenge with dye. *Cathet Cardiovasc Diagn* 1993;**28**:149–51.
13. **Rapoport SI**, Hori M, Klatzo I. Reversible osmotic opening of the blood–brain barrier. *Science* 1971;**10**:1026–8.