

Diagnostic approach to assessment of valvular heart disease using MRI—Part I: a practical approach for valvular regurgitation

Lertlak Chaothawee

Department of Cardiology,
Bangkok Heart Hospital,
Bangkok, Thailand

Correspondence to

Dr Lertlak Chaothawee,
Department of Cardiology,
Bangkok Heart Hospital, 2 Soi
Soonvijai, Petchaburi Road,
Bangkok 10310, Thailand;
chaothawee@yahoo.com

Accepted 29 January 2012

ABSTRACT

Valvular heart diseases from any cause are divided into two categories: stenosis and regurgitation. Acquired knowledge of the pathological aetiology and disease severity are the important clues for optimal treatment, which may be medication or combination with surgery. The non-invasive techniques have been established for valvular heart disease evaluation for many years especially in demonstrating valvular structure and assessing severity. Transthoracic echocardiography still plays the major role. However, not every case can be clearly evaluated by transthoracic echocardiography because of rib space window limitation. In the present-day practice, MRI has been extensively used for the evaluation of heart diseases in both unique and complementary categories. However, valvular heart disease assessment using cardiac MRI still remains an important challenge.

INTRODUCTION

Valvular heart diseases from any cause can be categorised into two functional categories: stenosis and regurgitation. Being able to understand the pathological aetiology and disease severity are important for the optimal treatment of the underlying condition. Non-invasive techniques have been established for the evaluation of valvular heart disease for many years, especially in demonstrating valvular structure and assessing severity. Transthoracic echocardiography still plays the major role. However, not every case can be clearly evaluated by transthoracic echocardiography because of rib space window limitation. In the present-day practice, MRI has a well-established diagnostic role for heart disease as it has unique and complementary capabilities. While cardiac MRI is used to assess a wide range of heart conditions, valvular heart disease assessment by cardiac MRI continues to be challenging. In this article—Part I—the focus will be on the use of MRI in assessing valvular regurgitation. Valvular stenosis and prosthetic heart valve assessment will be included in Part II.

VALVULAR HEART DISEASE EVALUATION USING MRI

In evaluating valvular heart disease, the two key parameters that need to be assessed are valvular structure and flow. Similar to echocardiography, MRI must assess the type of flow across the valve as laminar flow or turbulent flow. *Laminar flow* is the normal state of blood flowing throughout most of the circulatory system and occurs when the fluid

flows smoothly in parallel layers with no disruption between the layers. Disruption of laminar flow leads to turbulence that increases flow energy loss in the form of friction so turbulence requires more energy to drive blood flow.¹ Flow through a narrow or leaky valve, at the branch point of a large artery and through the narrowed segment of an artery causes turbulent flow and produces murmur. The high velocity flow and turbulent flow give rise to a dark signal void in gradient echo CINE-MRI image.² In MRI, signal void is a region emitting no radiofrequency signal because there are no activated protons in the region (such as flowing blood) or because of uncompensated dephasing.³ Signal void can be simply categorised into physiological and pathological signal void according to the type of source. Physiological signal void is normally observed in the heart chambers and often occurs at the area that has some minor flow disruption caused by normal anatomical structures, for example, signal flow void is present at the mid ventricular area where the papillary muscle acts as a physiological disruptor.

In practical application, dark intensity signal void is always used as a marker for the presence of an abnormally high velocity forward flow, running across the stenotic valve into the receiving chamber downstream and of the high velocity regurgitant flow that leaks into the receiving chamber upstream due to incompetent cardiac valve closure. Two key MRI techniques are used in valvular heart disease assessment: gradient echo CINE-MRI and phase contrast quantification (Q) flow mapping MRI. Gradient echo CINE-MRI is used to demonstrate the character and the extension of the abnormal flow including the valve structure while phase contrast Q flow mapping MRI is used to measure the velocity, volume and fraction of flow across the valve in any direction and location.⁴ To quantify the flow by phase contrast Q flow MRI, the acquisition plane of the locator must be perpendicular to the valve or vessel of interest (through-plane). To qualitatively visualise the flow direction, the slice plane must be parallel to the flow axis (in-plane). For flow assessment by phase contrast Q flow mapping MRI technique, positioning of the locator slice including the flow direction specification are very important factors that affect the accuracy of the result. The optimal position of the locator slice placement is determined by the pathophysiology of the diseased valve, depending on whether it is stenosis or regurgitation. Only the flow volume that is included into the locator slice thickness or slice box at the specified position is captured and

measured in all cardiac phases. By the theory of phase contrast imaging, flow volume and velocity are mapped because the change of flowing spins phase (phase shift of moving tissue) which is relative to the stationary spins (stationary tissue) is directly proportional to the flow velocity.⁵ Phase contrast Q flow imaging produces two types of images: without and with flow encoding that provide the qualitative magnitude image for anatomical data and the quantitative phase image for flow volume and velocity data, respectively.⁵ Similar to Doppler echocardiography, by using colour coding on the phase contrast imaging we can see the 'flow away from the viewer' (antegrade flow) in red and the 'flow towards the viewer' (retrograde flow) in blue as compared with the 'normally seen' with no colour coding in bright and dark signal respectively on the through-plane images. In addition, using phase contrast Q flow mapping technique requires a suitable velocity encoding (VENC) speed which must be adjusted beforehand to avoid an aliasing effect when measuring high velocity. VENC should be above the expected maximum velocity of flow.^{6,7} The importance of VENC adjustment is usually observed in valvular stenosis evaluation. To obtain an accurate result, retrospective cardiac gating is also applied to both gradient echo CINE- MRI and phase contrast flow mapping MRI. This results in imaging throughout all phases of the cardiac cycle.⁸

VALVULAR REGURGITATION ASSESSMENT USING MRI

Valvular regurgitation is a consequence of incomplete valve closure. The incomplete valve closure results in the production of high velocity jet of regurgitant flow and leaks back to the upstream chamber. Factors that determine the amount and the direction of regurgitant jet include size and shape of orifice,

regurgitant volume, driving force, receiving chamber constraint, wall impingement, timing relative to cardiac cycle and influence of coexisting jets or flow stream.⁹ The regurgitant volume and regurgitant fraction (RF) are the most important key factors for assessing regurgitation severity. In addition, other parameters are used to assess the severity of valvular regurgitation indirectly when using MRI, such as the length of signal void, the vena contracta width and the regurgitant orifice area (ROA). These parameters have been proposed for evaluating valvular regurgitation in the American College of Cardiology/American Heart Association (ACC/AHA) practice guidelines for valvular heart disease management.¹⁰ In the absence of well-established MRI criteria for assessing valvular heart disease, the echocardiographic criteria for valvular regurgitation severity interpretation has been adopted as reference for the MRI application (table 1).

PRACTICAL APPROACH TO MRI ASSESSMENT OF VALVULAR HEART DISEASE

Direct measurement of regurgitant flow and fraction

Direct measurement of the regurgitant flow and RF are obtained by using phase contrast Q flow mapping imaging by relying on the principle of difference between forward and backward flow volume across the assessed valve within the locator slice thickness box at that specific position. This technique can be applied in both single regurgitation and multiple regurgitation cases. For this technique, selection of the reference image and plane for flow study of the assessed valve is very important and must be performed as the first step by using the gradient echo CINE-MRI. The horizontal four-chamber view image is used as the reference image for the atrioventricular valves. The coronal view image is used for the aortic valve and sagittal view image is used

Table 1 Classification of the severity of regurgitation valve in adults (Source: ACC/AHA practice guidelines 2006)

	Mild	Moderate	Severe
Aortic regurgitation			
Qualitative			
Angiographic grade	1+	2+	3+
Colour Doppler jet width (cm)	Central jet width <25% of LVOT	Greater than mild but no signs of severe AR	Central jet, width >0.6
Vena contracta width (cm)	<0.3	0.3–0.6	>0.6
Quantitative			
Regurgitation volume (ml per beat)	<30	30–59	≥60
Regurgitant fraction (%)	<30	30–49	≥50
Regurgitant orifice area (cm ²)	<0.10	0.10–0.29	≥0.30
Additional essential criteria			
Left ventricular size			Increased
Qualitative mitral regurgitation			
Angiographic grade	1+	2+	3–4+
Colour Doppler jet area	Small central jet (<4 cm ² or <20% of the left atrium)	Signs of MR greater than mild present but no criteria for severe MR	
Vena contracta width (cm)	<0.3	0.3–0.69	≥0.70
Quantitative			
Regurgitation volume (ml per beat)	<30	30–59	≥60
Regurgitant fraction (%)	<30	30–49	≥50
Regurgitant orifice area (cm ²)	<0.20	0.10–0.39	≥0.40
Additional essential criteria			
Left atrial size			Increased
Left ventricular size			Increased
Right sided valve			
Severe tricuspid regurgitation	Vena contracta width >0.7 cm ²		
Severe pulmonic regurgitation	Colour jet fill outflow tract		

AR, aortic regurgitation; LVOT, left ventricular outflow tract; MR, mitral regurgitation.

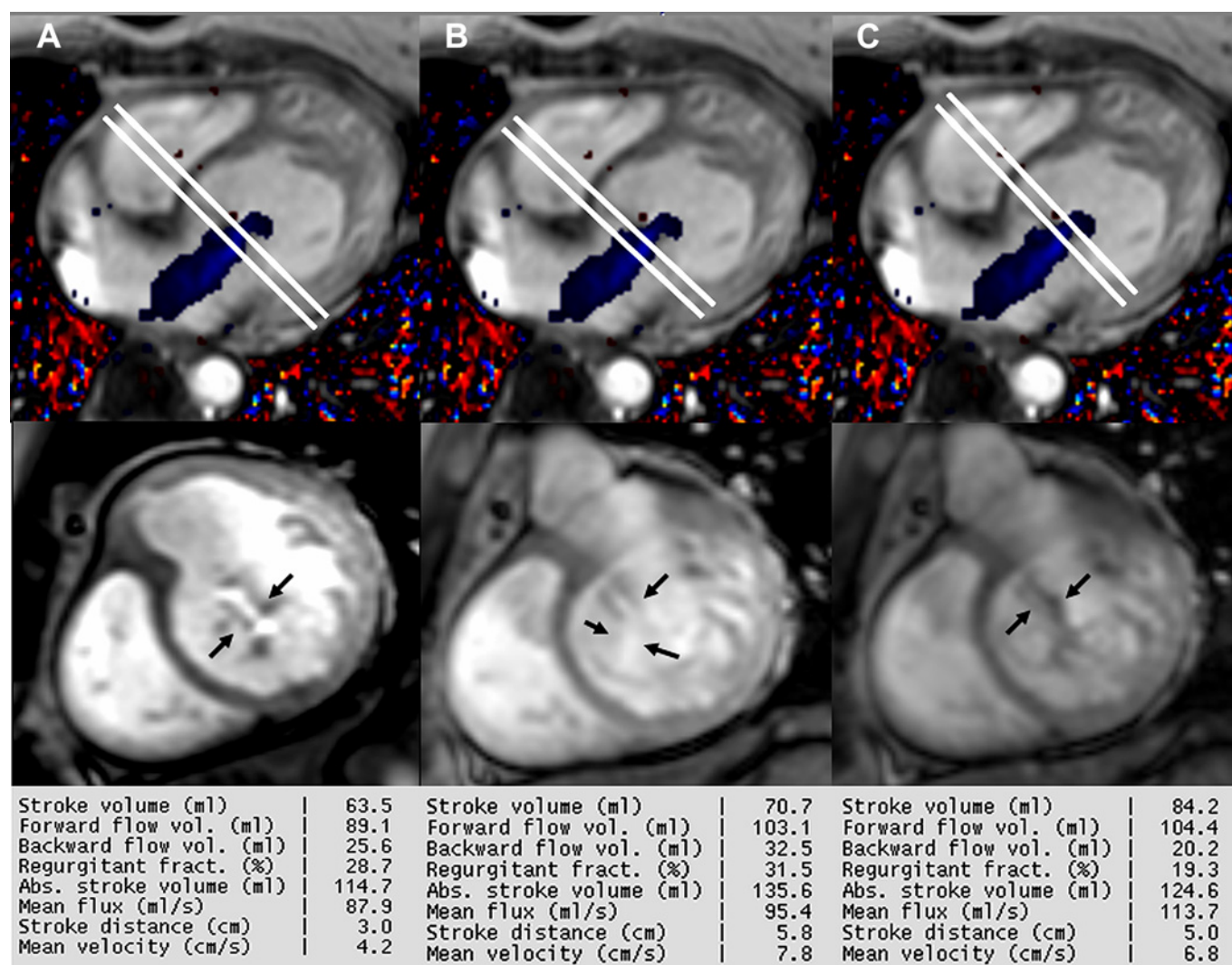
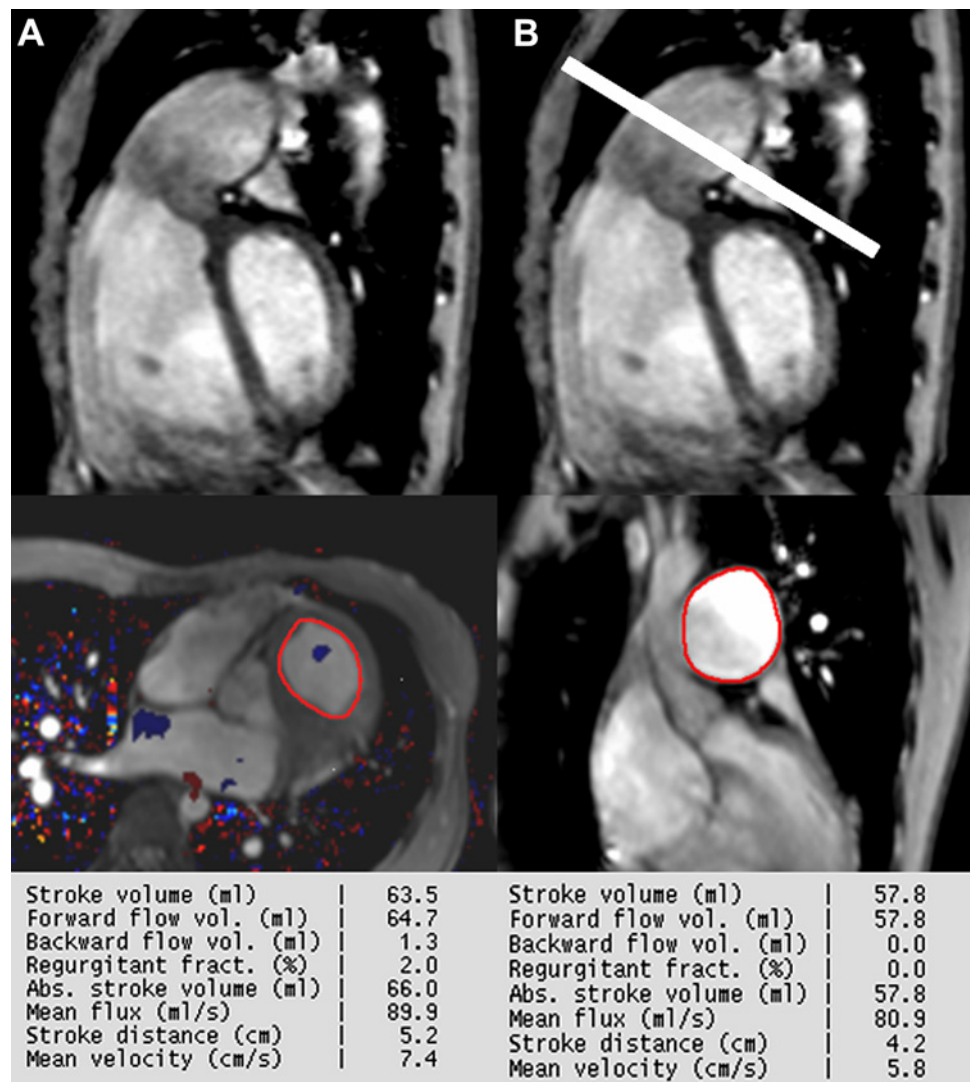


Figure 1 Demonstration of the mitral regurgitant volume measurement by using phase contrast Q flow mapping imaging and using the gradient echo CINE image in four-chamber view for the reference images. (A) The locator slice is placing at the closing tip position and the slice thickness is adjusted to cover the first phase of the valve closing (the phase that valvular cusps have first touched each other). (B) The locator slice is placing too proximal against to the valve closing position which causes the overestimation of the mitral regurgitant volume because of the ROA is technically made larger than expectation. (C) The earliest systolic phase of valve closing moves away from the locator slice because the locator is placed too distal to cover the earliest phase of valve closing that causes the underestimation of the mitral regurgitant volume. By this method the regurgitant volume at the earliest systolic phase of valve closing is lost. Color Doppler in blue represents the regurgitant flow (arrow indicates ROA).

for the pulmonary valve. Because the regurgitant flow direction is not always in the central line and the entire direction and the entire length or the entire amount of the regurgitant flow void cannot be demonstrated in only one image slice, multiple slices of the CINE image in optimal views should be obtained and the largest anatomical area of the receiving chamber must be shown. The second step is to measure the regurgitant volume and RF. Regurgitant flow is produced when the valve closes; therefore to measure the RF of any valve by using phase contrast Q flow mapping technique, the locator slice must be placed perpendicular to the regurgitant flow direction or the assessed valve and importantly, for atrioventricular valves, the locator slice thickness box must include the valve tip in the first phase of valve closure (the phase that valvular cusps have first touched each other) because of the fact that the largest amount of regurgitant volume per phase and the largest ROA are obtained at the earliest or first phase of valve closure. With this method, the true maximum ratio of the forward to the backward flow is provided

(figure 1A). By the principle of RF measurement by phase contrast Q flow mapping MRI as previously mentioned, only the flow volume within the locator slice thickness box at the specified position is measured and assessed. The RF will be overestimated if the locator slice is placed at the very proximal position of the valve leaflet (ie, at the line of the anterior–posterior mitral leaflets insertion) and the locator slice box does not include the first phase of valve closure (the image of the closing valve tip at the first phase is not within the slice thickness box). This makes the duration time of regurgitation seem longer (the blue colour coding regurgitant flow is still seen in the diastolic phase) and the ROA seems larger than usual (figure 1B). Thus, the total amount of the included regurgitant volume within the locator slice box is technically increased. If the locator slice is placed at the very distal or tip of the valve during the widest opening, the first valve touching phase may move out of the locator slice box during the period of valve closing. There will be underestimation of the regurgitation fraction because the

Figure 2 Demonstration of the different value of the right ventricular stroke volume and pulmonic regurgitant volume in different measurement location. (A) The locator slice is placed at the RVOT (right ventricular outflow tract) position. (B) The locator slice is placed at the mid main pulmonary artery. The total stroke volume at the RVOT is the summation of forward and backward volume but the stroke volume at the mid main pulmonary artery is equal to the forward stroke volume.



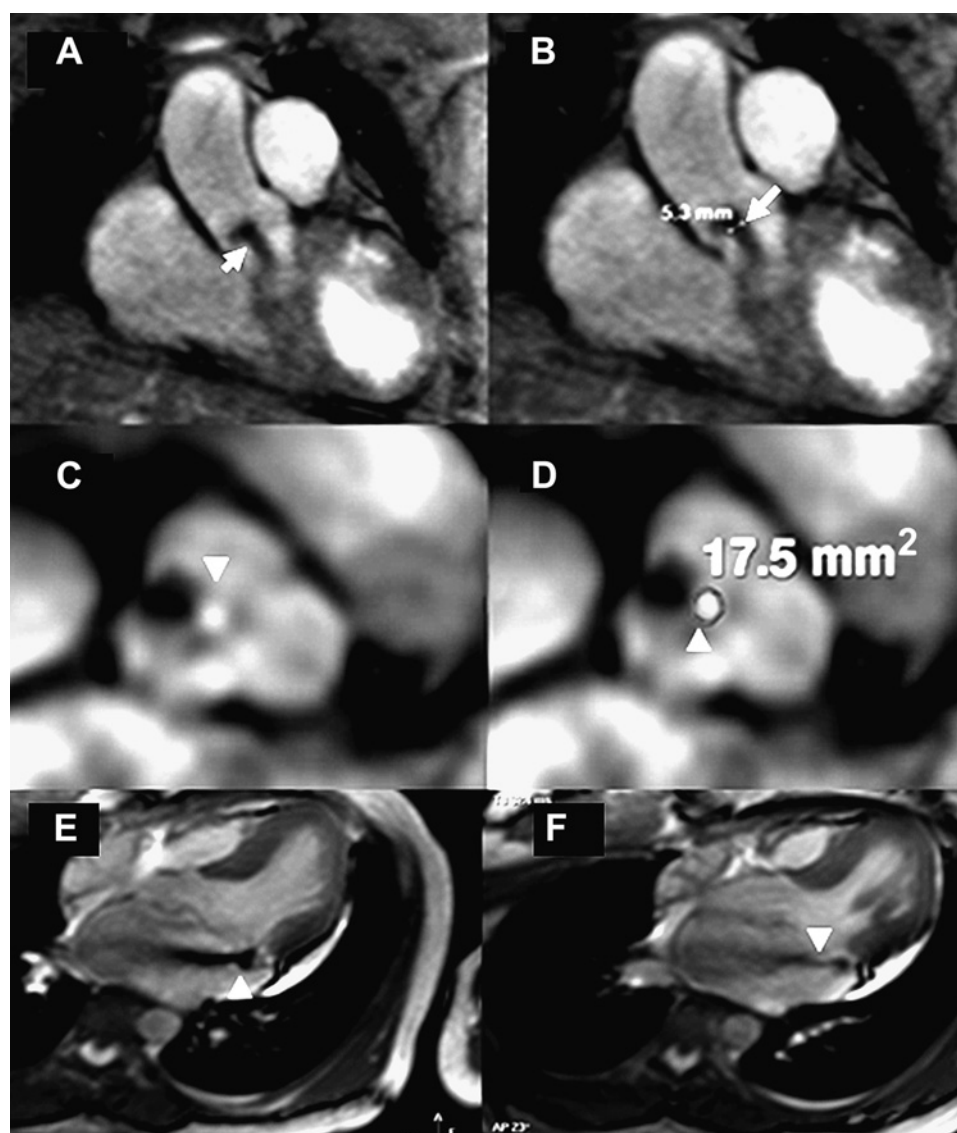
maximum regurgitant volume phase is lost (figure 1C). To measure the pulmonary regurgitation and the aortic regurgitation fraction, it is recommended that the locator slice box be placed perpendicular to the flow at the right ventricular outflow tract and the left ventricular outflow tract (LVOT), respectively. In addition, the upper rim of the locator slice box must close to the base of the closing valve in diastolic phase. By this method, the effective regurgitant volume (and fraction) which provides the real effect to the amount of receiving ventricular chamber stroke volume is obtained (figure 2).

Regurgitant flow volume and fraction calculation

The calculation of regurgitant volume is by the principle of the volume difference between ventricular stroke volume that receives the blood flow across the assessed valve and the forward stroke volume through the great vessel that is on the same side as the assessed valve. For example, the calculated mitral regurgitant volume (MRV) is obtained by the difference between the left ventricular stroke volume (LVSF) and the aortic forward stroke volume (AoSF), that is, $MRV \text{ (ml/beat)} = LVSF - AoSF$. The RF is the ratio of the MRV divided by the LVSF that is, $RF \text{ (%) } = (MRV / LVSF) \times 100$.^{11 12} By this method, ventricular stroke volume is the volume difference between the ventricular end diastolic volume and the ventricular end systolic volume which are accurately obtained in diastole and systole respectively with

slice summation method or volumetry method of the ventricle by using the gradient echo CINE-MRI.^{13–15} Effective forward stroke volume through the great vessel is obtained by gradient echo Q flow mapping MRI technique at the mid ascending aorta or mid main pulmonary artery. The mid ascending aorta and the mid main pulmonary artery are the proper and ideal positions for effective forward stroke volume measurement because they are at the proximal part of the circulation system where the total effective forward stroke volume passes before going through the circulation. The differences of the values of the forward stroke volume are observed in the different mapping locations when using phase contrast Q flow sequence (figure 2). To calculate regurgitant volume by the principle of the difference of stroke volume between both ventricles or between the forward flow stroke volume of the great vessels may be used but they are valid in only cases of single regurgitation valve. In cases of combined aortic and mitral regurgitation, the difference represents the sum of regurgitant volume.^{16 17} However, in the case of multiple valves regurgitation (especially they are in the same side, such as combination between aortic regurgitation and mitral regurgitation), MRI Q flow mapping technique can be applied by mapping at the LVOT level (or RVOT level in case of combined pulmonic and tricuspid regurgitation) as mentioned in the topic of direct flow measurement by phase contrast Q flow technique. At this mapping location, the stroke volume that is ready to go

Figure 3 (A,B) Demonstration of the vena contracta width (arrow) of aortic regurgitation. (C,D) Demonstration of the ROA measurement (arrow) of the aortic valve. (E,F) Demonstration of the difference of the extension of the regurgitant signal void and the vena contracta width in different image slice of gradient echo MR images. Measurement must be done on the image slice which demonstrates the longest extension of the signal void and the widest vena contracta (E).



through the aortic valve by ventricular contraction will include the effective forward stroke volume and the aortic regurgitant volume (figure 2A). With this method, the MRV is obtained by the difference between the LVSV and the absolute AoSV. By the principle of volume difference, AoSV at the level of mid ascending aorta = effective forward stroke volume (does not include the aortic regurgitant volume), LVOT stroke volume = effective forward stroke volume + aortic regurgitant volume, LVSV = forward stroke volume + MR volume, MR volume = LVSV – LVOT volume. For assessment of the regurgitant volume and fraction for the atrioventricular valves by using MRI, the calculation method is also recommended. For the semilunar valves, direct method by phase contrast imaging is a more convenient method.

Estimation of severity of valvular regurgitation by vena contracta width, regurgitant orifice area and extension of the signal void

Vena contracta (figure 3A,B) is defined as the narrowest central flow region of a jet that occurs at, or just downstream to the orifice of a regurgitant valve.⁹ It is characterised by high velocity laminar flow. Vena contracta reflects the diameter of the regurgitant orifice but it is slightly smaller than the anatomic regurgitant orifice due to boundary effects.⁹ The size is independent of flow rate and driving pressure for a fixed orifice. If the regurgitant

orifice is dynamic, the vena contracta may change with haemodynamics, or during the cardiac cycle. Because of the small values of the width of the vena contracta (usually <1 cm), small errors in its measurement may lead to a large per cent error and misclassification of the severity of regurgitation.⁹ However, vena contracta width measurement can be very easily performed on the reference gradient echo MR images in the optimal view. Obtaining multi-image slices on the selected plane is strongly recommended for vena contracta width measurement. The image that provides the largest vena contracta width is selected. Usually, the optimal image for vena contracta width measurement is a gradient echo MR image that is selected as a reference image for flow measurement by phase contrast Q flow mapping MRI.

ROA (figure 3C,D), by definition, is the area through which the valve leaks. ROA measurement is another method for quantifying the degree of valvular regurgitation by determining the area of the regurgitant flow at the level of the valve when the valve is closing. The ROA correlates with the size of the defective valve. ROA can be obtained by using gradient CINE-MRI or phase contrast Q flow mapping MRI by placing the locator slice in the same way as done in direct regurgitant flow measurement by using phase contrast MRI. This method is used for all cardiac valves. The earliest cardiac phase of the valve closing will produce the phase of widest vena contracta width

and the widest ROA. Good correlation between the vena contracta width and ROA is shown in figure 3A–D. Vena contracta and ROA can be used conveniently for determination of valvular regurgitation severity in all cardiac valves.

Another method for quantification of valvular regurgitation is to measure the extension of the regurgitation signal void that can be done on the CINE-MRI images.^{12–18} Regurgitant signal void extension (figure 3E,F) is a parameter that correlates very well with the amount of regurgitation volume. The diastolic retrograde flow void equals regurgitant volume and correlates closely with volumetric CINE-MRI in the case of aortic regurgitation.¹⁶ The site of the jet affects the measured grade of regurgitation. For example, the mitral regurgitant jets which are peripheral eccentric move or slide on a wall that causes underestimation up to 40% of regurgitation severity as compared with jets that are central to the surface adherence.^{19–20} To measure the regurgitant signal void extension required image selection to demonstrate the longest extension of the signal void. The best method is to obtain multiple slices to cover the entire receiving chamber in the optimal views of the assessed valve.

CONCLUSION

MRI has great potential use in the evaluation of valvular regurgitation because it is capable of both demonstrating the valvular structure and recording the flow parameters of the assessed valve. MRI has an advantage over echocardiography by providing direct evaluation methods for assessing valvular regurgitation anatomy and flow without angle limitation. Phase contrast Q flow mapping MRI technique can be used to directly measure the RF effectively in both single and multiple regurgitations. To prevent erroneous measurements in MRI use, care is needed in reference image selection and locator slice positioning. Vena contracta width, ROA and signal void extension are used as indirect indicators for regurgitation severity and they can be used as intra-modality confirmation tools for checking the consistency of the results obtained by direct measurement method. The main drawback of MRI in valvular regurgitation assessment is that it is time-consuming and hence, good protocol planning is needed.

Acknowledgements The author thanks Dr Gumpanart Veerakul, the president of the Cardiovascular and Prevention Center, Bhumbol Adulyadej Hospital, Royal Thai Airforce, Bangkok, Thailand and Dr Kit V Arom, the former director of Bangkok Heart Hospital, Bangkok, Thailand for the encouragement. Thanks to nurses and technicians of cardiac imaging unit, Bangkok Heart Hospital, Bangkok, Thailand for the great support.

Contributors Dr Pradub Sukum (the director of the Bangkok Heart Hospital, Bangkok, Thailand) provides general support 2. Cardiac imaging team: working cooperation Nurses and technicians 1. Mrs Duddao Pantunurat R N 2. Mrs Yanipa Keawlumhud R

N 3. Miss Darunee Jaiyong R N 4. Miss Sangrawee Sri-ngam R T 5. Miss Paweena Mapinta R T 6. Miss Pornpanus Kaewchai R T 7. Mr Busakol Ngammaung R T.

Competing interests None.

Patient consent Obtained.

Provenance and peer review Commissioned; internally peer reviewed.

REFERENCES

1. Klabunde RE. *Cardiovascular Physiology Concept*. 1st edn. Philadelphia: Lippincott Williams and Wilkins, 2004.
2. Didier D, Ratib O, Lerch R, et al. Detection and quantification of valvular heart disease with dynamic cardiac MR imaging. *Radiographics* 2000;**20**:1279–99.
3. Keegan J, Gatehouse PD, John AS, et al. Breath-hold signal loss sequence for the qualitative assessment of flow disturbances in cardiovascular MR. *J Magn Reson Imaging* 2003;**18**:496–501.
4. Reimer P, Boos M. Phase-contrast MR angiography of peripheral arteries: technique and clinical application. *Eur Radiol* 1999;**9**:122–7.
5. Suzuki JI, Caputo GR, Kondo C, et al. Cine MR imaging of valvular heart disease: display and imaging parameters affect the size of the signal void caused by valvular regurgitation. *AJR Am J Roentgenol* 1990;**155**:723–7.
6. Evans DH, McDicken WN, Skidmore R, et al. *Doppler Ultrasound: Physics, Instrumentation, And Clinical Applications*. Chichester: Wiley, 1989.
7. Lotz J, Meier C, Leppert A, et al. Cardiovascular flow measurement with phase-contrast MR imaging: basic facts and implementation. *Radiographics* 2002;**22**:651–71.
8. Lee VS. *ECG Gating in Cardiovascular MRI: Physical Principles to Practical Protocols*. Philadelphia, PA: Lippincott Williams & Wilkins, 2006:257–65.
9. Catherine M, Otto MD. *Valvular regurgitation: Textbook of clinical echocardiography*. 3rd edn. Philadelphia: Saunders, 2004.
10. Bonow RO, Carabello BA, Chatterjee K, et al. ACC/AHA practice guidelines. *J Am Coll Cardiol* 2006;**48**:e1–148.
11. Pepper J, Pennel D, Kilner P. Towards comprehensive assessment of mitral regurgitation using cardiovascular magnetic resonance. *J Cardiovasc Magn Reson* 2008;**10**:61.
12. Higgins C. Valvular heart disease. In: Webb R, Higgins C, eds. *Thoracic Imaging-Pulmonary and Cardiovascular Radiology*. Philadelphia: Lippincott Williams and Wilkins, 2005:707–19.
13. Jenkins C, Bricknell K, Hanekom L, et al. Reproducibility and accuracy of echocardiographic measurements of left ventricular parameters using real-time three-dimensional echocardiography. *J Am Coll Cardiol* 2004;**44**:878–86.
14. Djavidani B, Schmid FX, Keyser A, et al. Early regression of left ventricular hypertrophy after aortic valve replacement by the Ross procedure detected by cine MRI. *J Cardiovasc Magn Reson* 2004;**6**:1–8.
15. Francois CJ, Fieno DS, Shors SM, et al. Left ventricular mass: manual and automatic segmentation of true FISP and FLASH cine MR images in dogs and pigs. *Radiology* 2004;**230**:389–95.
16. Heinle S. Quantitation of valvular regurgitation. In: Otto C, ed. *The Practice of Clinical Echocardiography*. 2nd edn. Philadelphia: W.B. Saunders, 2002:367–88.
17. Fujita N, Chazouilleres AF, Hartiala JJ, et al. Quantification of mitral regurgitation by velocity-encoded cine nuclear magnetic resonance imaging. *J Am Coll Cardiol* 1994;**23**:951–8.
18. Bonow R, Braunwald E. Valvular heart disease. In: Zipes D, Libby P, Bonow R, et al, eds. *Braunwald's Heart Disease*. 7th edn. Philadelphia: Elsevier Saunders, 2005:1572.
19. Chao K, Moises V, Shandas R, et al. Influence of the Coanda effect on colour Doppler jet area and colour encoding: In vitro studies using colour doppler flow mapping. *Circulation* 1992;**85**:333–41.
20. Sugeng L, Spencer K, Mor-Avi V, et al. Dynamic three-dimensional colour flow doppler: an improved technique for the assessment of mitral regurgitation. *Echocardiography* 2003;**20**:265.