

Shelled heart: tuberculous constrictive pericarditis

A 55-year-old man presented with progressive distension of the abdomen, pedal oedema, effort dyspnoea and excessive fatigue. Physical examination showed facial puffiness, distended neck veins with prominent Y descent in jugular venous pressure, ascites, systolic retraction of the chest wall and a loud pericardial knock. Echocardiography showed greatly thickened pericardium (figure 1A) with features of constrictive pericarditis. Thick pericardium was seen by MRI, with 20 mm thickness lateral to the left ventricle (figure 1B). Cardiac catheterisation disclosed prominent Y descent in right atrial tracing with no respiratory variation of the mean right atrial pressure (figure 1C). There was elevation and equalisation of right and left ventricular end diastolic pressures, prominent rapid filling wave and ventricular interdependence (figure 1D). Pericardiectomy was carried out through midline sternotomy, and histopathology showed caseating granuloma consistent with tuberculosis (figure 1E), which is

still the leading cause of constrictive pericarditis in developing countries.¹ The patient improved well after the surgery and anti-tuberculous treatment.

G Rajesh, Deepak Raju, M N Krishnan

¹Department of Cardiology, Government Medical College, Kozhikode, Kerala, India

Correspondence to Dr Deepak Raju, Department of Cardiology, Government Medical College, Kozhikode, Kerala 673008, India; drj980@gmail.com

Contributors All the authors made a substantial contribution to the concept, design and drafting of the article. The manuscript was read and approved by all the authors.

Competing interests None.

Provenance and peer review Not commissioned; internally peer reviewed.

To cite Rajesh G, Raju D, Krishnan MN. *Heart Asia* Published Online First: [please include Day Month Year] doi:10.1136/heartasia-2013-010363

Heart Asia 2013;0:127. doi:10.1136/heartasia-2013-010363

REFERENCE

- 1 Mayosi BM, Burgess LJ, Doubell AF. Tuberculous pericarditis. *Circulation* 2005;112:3608–16.

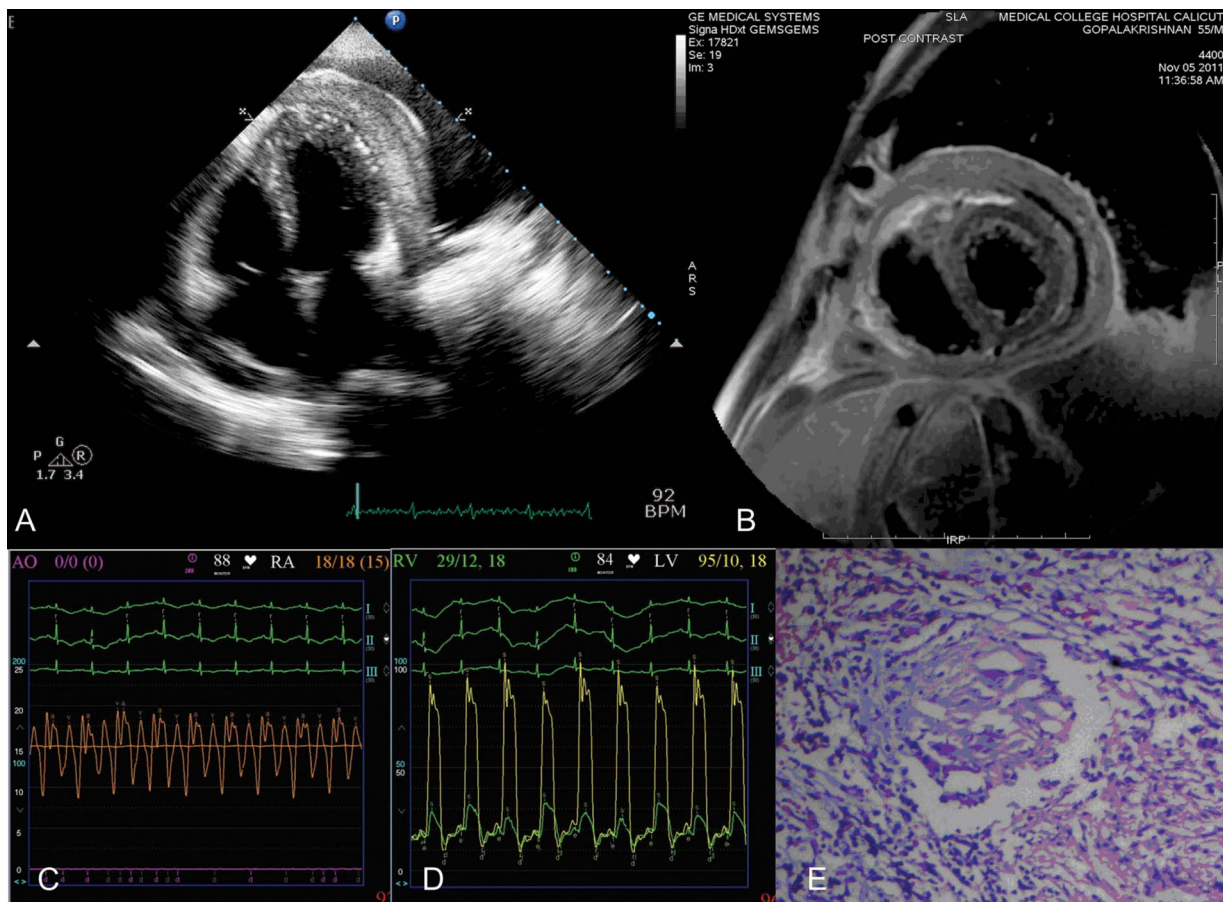


Figure 1 (A) Two-dimensional echocardiography, apical four-chamber view showing greatly thickened pericardium. (B) Contrast MRI showing thick pericardium. (C) Right atrial pressure tracing with prominent Y descent and no respiratory variation in mean pressure. (D) Simultaneous right ventricular (green) and left ventricular (yellow) pressure tracing demonstrating elevation and equalisation of end diastolic pressures, prominent rapid filling wave and ventricular interdependence. (E) Histopathology showing caseating granuloma.