

Renal artery pseudoaneurysm: an unexpected mode of closure during coil embolisation

A 32-year-old man was referred for evaluation of persistent haematuria following percutaneous nephrolithotomy (PCNL) for a right renal calculus. Examination revealed obvious pallor (Hemoglobin, 6 g/dL), tachycardia (130 bpm) and hypotension (80/60 mm Hg), with frank blood in the urobag. Patient was afebrile. He was stabilised with intravenous fluids and blood transfusions. CT of renal arteries was suggestive of leaking pseudoaneurysm from right posterior lower pole interlobar renal artery.

Renal angiography was undertaken to confirm the pseudoaneurysm and plan for selective coil embolisation. It revealed a focal pseudoaneurysm arising from the right lower pole interlobar renal artery (figure 1A). A 4-Fr cobra catheter was selectively placed beyond the origin of the feeding artery (figure 1B). Prior to deployment of the coil, the renal artery went into severe spasm and the entire system was withdrawn (figure 1C). The spasm was relieved after administration of vasodilators (nitroglycerin and diltiazem). However, the pseudoaneurysm was not visualised thereafter and subsequently after 48 h (figure 1D). There was no evidence of haematuria after 4 days. He improved clinically and was discharged 1 week after admission. At 1 year follow-up, patient is asymptomatic.

Persistent haematuria following PCNL is a rare, but known complication. Differential diagnoses include pseudoaneurysm, arteriovenous fistula and pyelonephritis. The reported incidence of vascular complications in surgical procedures like pyelolithotomy is 0.1%–0.3%.¹ Clinical symptoms, aneurysm size and renal impairment are the indications for treatment in pseudoaneurysm.² The non-surgical treatment options for renal artery pseudoaneurysm include angiographic embolisation³ and percutaneous thrombin injection.⁴ In the present report, pseudoaneurysm had closed due to probable spasm and thrombosis (hardware-induced) during attempted coil embolisation. This modality of closure is unusual. Surgery is indicated when main renal artery is involved and in patients who are unstable despite minimally invasive techniques. To conclude, although uncommon, renal artery pseudoaneurysm is one of the major complications following PCNL and can lead to life threatening haematuria. Spasm of renal artery and subsequent thrombosis, provoked during therapeutic catheterisation, may result in inadvertent closure of pseudoaneurysm, averting the need for deployment of coils.

Srinivasa K Hemanna Setty, Rajiv Ananthakrishna, Manjunath C Nanjappa

Department of Cardiology, Sri Jayadeva Institute of Cardiovascular Sciences & Research, Bangalore, Karnataka, India

Correspondence to Dr Rajiv Ananthakrishna, Department of Cardiology, Sri Jayadeva Institute of Cardiovascular Sciences & Research, Jaya Nagar 9th Block, BG Road, Bangalore, Karnataka 560069, India; rajiva.ms@gmail.com

Contributors All authors have contributed to diagnostic work-up, planned intervention and write up.

Competing interests None.

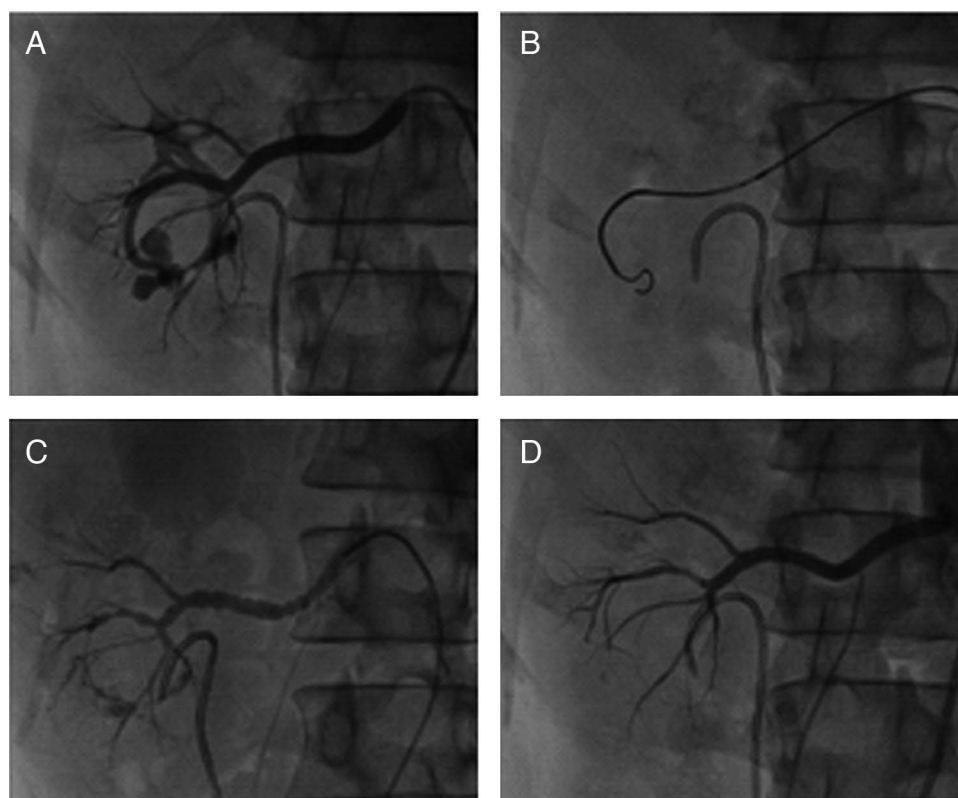


Figure 1 (A) Diagnostic renal angiogram: A focal pseudoaneurysm arising from right interlobar lower pole renal artery. In addition, proximal end of Double J stent noted in situ. (B) Fluoroscopy: Terumo wire and 4-Fr cobra catheter to enter the pseudoaneurysm. (C) Renal angiogram: Spasm of the renal artery during attempted coil embolisation. (D) Check angiogram: No evidence of pseudoaneurysm, following attempted coil embolisation.

Patient consent Obtained.

Ethics approval Ethics approval was obtained from the Sri Jayadeva Institute of Cardiovascular Sciences and Research Ethics committee.

Provenance and peer review Not commissioned; externally peer reviewed.

To cite K Hemanna Setty S, Ananthakrishna R, Nanjappa MC. *Heart Asia* 2013;**5**:220–221. doi:10.1136/heartasia-2013-010314

Heart Asia 2013;**5**:220–221. doi:10.1136/heartasia-2013-010314

REFERENCES

- 1 Ansari MS, Dodamani D, Aron M, *et al.* Iatrogenic renal pseudoaneurysm after pyelolithotomy. *Ann Saudi Med* 2003;**23**:301–3.
- 2 Smith JN, Hinman F. Intrarenal arterial aneurysms. *J Urol* 1967;**97**:990–6.
- 3 Dinkel HP, Danuser H, Triller J. Blunt renal trauma: minimally invasive management with microcatheter embolization experience in nine patients. *Radiology* 2002;**223**:723–30.
- 4 Gupta V, Galwa R, Khandelwal N, *et al.* Postpyelolithotomy renal artery pseudoaneurysm management with percutaneous thrombin injection: a case report. *Cardiovasc Intervent Radiol* 2008;**31**:422–6.