

# An unusual presentation of external iliac artery pseudo aneurysm

A 48-year-old woman presented with acute onset of abdominal pain and vomiting. Examination revealed tenderness in the right iliac fossa with diminished bowel sounds. She had undergone coronary angioplasty 4 weeks previously via a right femoral artery (FA) approach. The FA access site was normal. Sonography of the abdomen revealed an appendicular mass. In view of the recent intervention via the right FA, the possibility of intraperitoneal collection or infected pseudo aneurysm in the pelvic vessels was considered. A 64 slice CT of the abdomen showed a pseudo aneurysm (80×60 mm) of the right external iliac artery (EIA) (figure 1A, B). She underwent resection of a segment of the right EIA involving the aneurysm, with placement of a Dacron graft between the right common iliac and the common FA.

Interventions via the right FA can be associated with local complications, such as haematoma, pseudo aneurysm, dissection and sometimes retroperitoneal haematoma in the case of high puncture. A pseudo aneurysm can rarely occur in the EIA or

higher up due to injury to the vessel wall caused by stiff guide-wires. This can be missed clinically because of the absence of any external swelling or lack of pain or tenderness. A strong suspicion of infected pseudo aneurysm in more proximal vessel has to be considered when these types of patients present with features of acute appendicitis. A 64 slice CT of the abdomen may be an ideal investigation in such cases.

**Kalathingathodika Sajeer, Chakanalil Govindan Sajeer, Kader Muneer, Mangalath Narayanan Krishnan**

Department of Cardiology, Government Medical College, Kozhikode, Kerala, India

**Correspondence to** Dr K Sajeer, Department of Cardiology, Government Medical College, Kozhikode 673008, Kerala, India; [drsajeerk@gmail.com](mailto:drsajeerk@gmail.com)

**Contributors** All authors contributed equally in preparing the manuscript.

**Competing interests** None.

**Patient consent** Obtained.

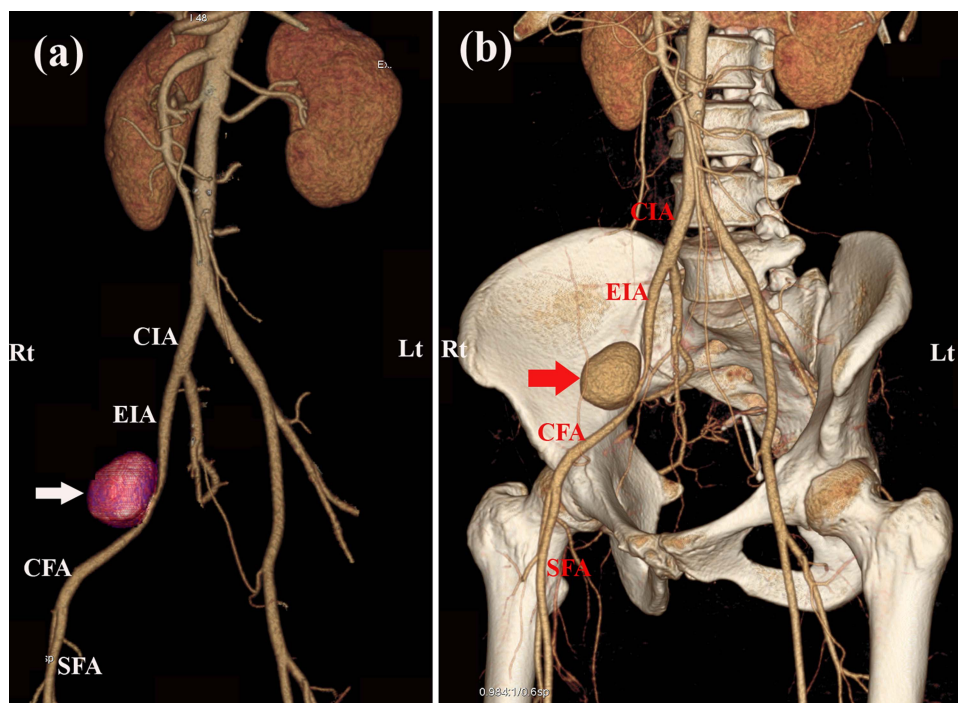
**Provenance and peer review** Not commissioned; externally peer reviewed.



CrossMark

**To cite** Sajeer K, Sajeer CG, Muneer K, et al. *Heart Asia* 2013;5:263. doi:10.1136/heartasia-2013-010481

*Heart Asia* 2013;5:263. doi:10.1136/heartasia-2013-010481



**Figure 1** (A, B) A 64 slice CT scan reconstructed image showing the external iliac artery pseudo aneurysm (arrow). CFA, common femoral artery; CIA, common iliac artery; EIA, external iliac artery; SFA, superficial femoral artery.