Percutaneous coronary intervention guided by the combination of computed tomographic angiography and optical coherence tomography

A 70-year-old man, who was a current smoker with dyslipidaemia and hypertension, felt worsening exertional chest oppression and visited our hospital. Electrocardiogram showed a negative T wave in II, III and aVF leads, and transthoracic echocardiography showed a wall motion abnormality at the inferior wall. No elevation of cardiac enzyme was confirmed.

Computed tomographic angiography (CTA) revealed two serial stenotic lesions with calcium deposits in the right coronary artery (white arrowheads in figure 1A,B). Short-axial images showed positive remodelling and lumen oppression with large low-CT value plaque in both sites (figure 1C,F), and a 'signet ring-like appearance[1]' in the proximal (figure 1C).

Optical coherence tomography (OCT) demonstrated an ulcer-like lesion in the proximal (figure 1D) and superficial mixed thrombus with thin-cap fibroatheroma (TCFA) in the distal (figure 1G). CTA and OCT strongly suggested plaque vulnerablity and a high possibility of no reflow during percutaneous coronary intervention.[2] Using a distal protection device, we performed a balloon angioplasty and covered both plaques with a single bare metal stent. Though transient no flow had occurred

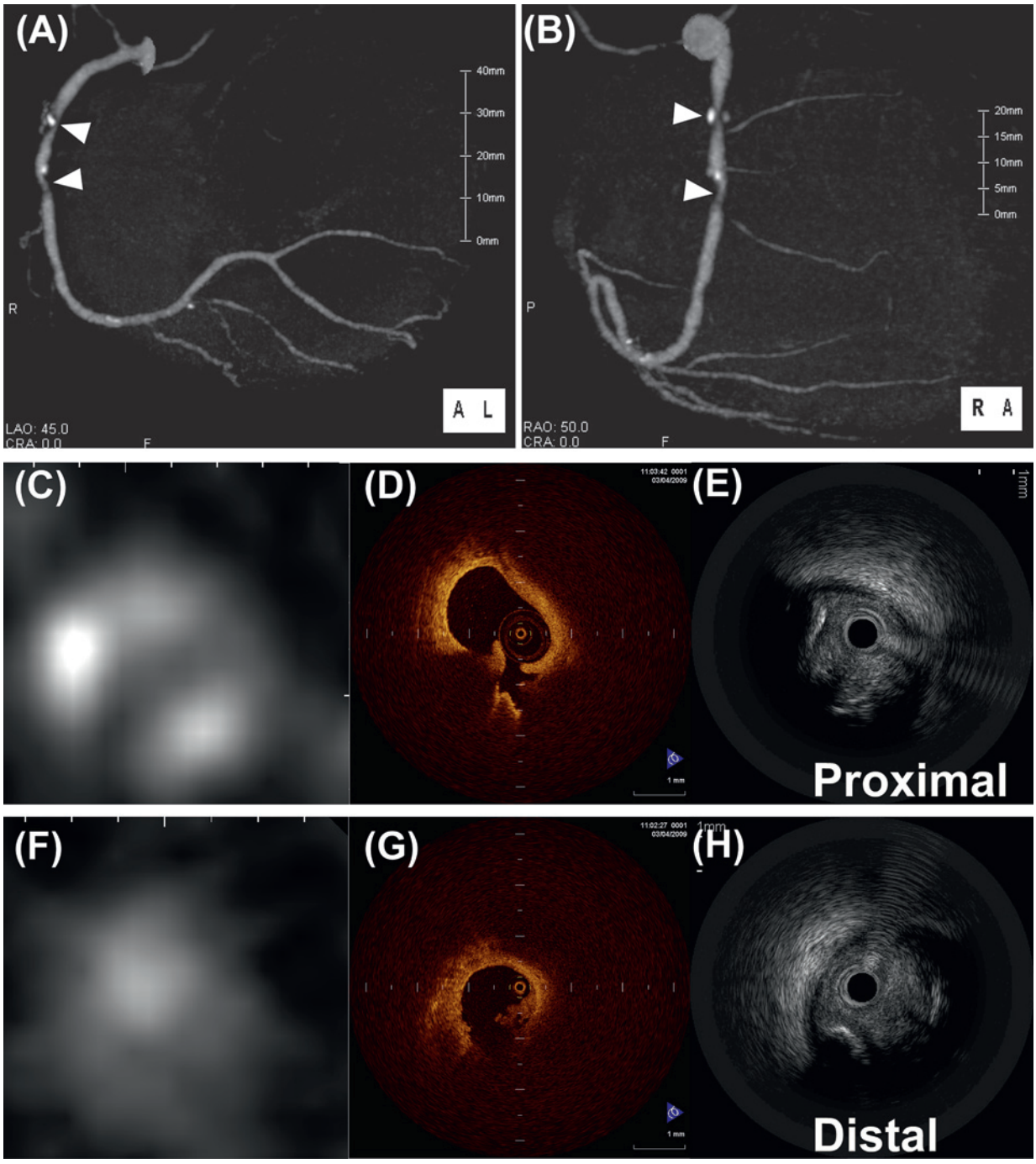

Figure 1

just after stenting, removal of the distal protection device improved coronary flow.

CTA showed the outline of coronary artery before the procedure. In addition, OCT gave us the local information in detail, and we were able to perform a safe and appropriate procedure. Although intravascular ultrasound also could reveal positive remodelling, large echolucent plaque with attenuation and small calcium deposits in both sites as shown in figure 1E,H, OCT detected only superficial thrombus, TCFA and stent apposition. In the case of scanning the coronary artery with CTA before percutaneous coronary intervention, OCT might be the best partner.

Tomofumi Takaya, Shinichiro Yamada, Takatoshi Hayashi

Department of Cardiology, Himeji Cardiovascular Center, Himeji, Japan

Correspondence to Dr Tomofumi Takaya, Department of Cardiology, Himeji Cardiovascular Center, 520, Saishoko, Himeji, 6700981, Japan; toto54@hotmail.com

Competing interests None.

Patient consent Obtained.

Provenance and peer review Not commissioned; not externally peer reviewed.

Heart Asia 2010:151—152. doi:10.1136/ha.2010.002055

REFERENCES

1. **Nakazawa G,** Tanabe K, Onuma Y, *et al*. Efficacy of culprit plaque assessment by 64-slice multidetector computed tomography to predict transient no-reflow phenomenon during percutaneous coronary intervention. *Am Heart J* 2008;**155**:1150—7.
2. **Kashiwagi M,** Tanaka A, Kitabata H, *et al*. Feasibility of noninvasive assessment of thin-cap fibroatheroma by multidetector computed tomography. *JACC Cardiovasc Imaging* 2009;**2**:1412—19.