Twenty-five-year-old woman with palpitations and hypertrophic cardiomyopathy

CLINICAL INTRODUCTION

A 25-year-old woman with a diagnosis of hypertrophic cardiomyopathy (HCM) and pre-excitation on ECG presented with unexplained syncope and daily palpitation. Genetic testing was positive for lysosome-associated membrane protein 2 (LAMP2) mutation which confirmed the diagnosis of Danon disease. Her younger sister was diagnosed with a similar condition and received a defibrillator implantation. Her 12-lead ECG (figure 1) and a long strip tracing (figure 2) are shown below.

QUESTION

Where is the location of the accessory pathway and what is the next appropriate management?

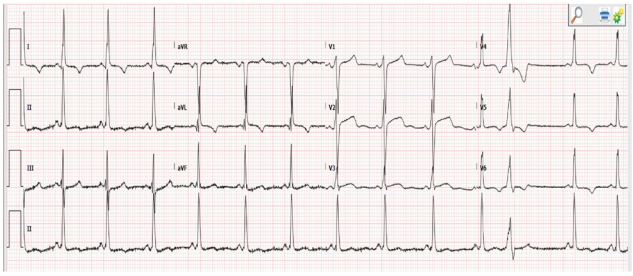

Figure 1 12-lead ECG.

A. Anteroseptal pathway and catheter ablation
B. Mid-septal pathway and pacemaker/defibrillator implantation
C. Right lateral pathway and catheter ablation
D. Fasciculoventricular pathway and electrophysiological study
E. Left lateral pathway and electrophysiological study

Figure 2 A long strip of the ECG tracing.

ANSWER: D

The correct answer is fasciculoventricular (FV) pathway and electrophysiological study should be the next step of management. Figure 1 demonstrates a 12-lead ECG showing sinus rhythm with a slightly short PR interval of 112 ms and evidence of pre-excitation, especially in precordial leads. The right lateral pathway would have a negative delta wave in lead V1 and left lateral pathway would have it in lead I and aVL. Figure 2 demonstrates a junctional rhythm on the first three beats and sinus rhythm on the last three beats of tracing. There is pre-excitation present as seen by slurring in upstroke of leads V2, V3, V4, and limb leads. Of note, the degree of pre-excitation is same in the sinus and junctional beats. In a typical atrioventricular accessory pathway, junctional beats will not show any pre-excitation since the depolarisation starts below the atrium and does not engage the accessory pathway. Hence, the finding of the similar degree of pre-excitation for junctional and sinus beat is diagnostic for FV pathway. Her electrophysiological study confirmed this diagnosis with a fixed HV interval. In addition, she had easily inducible atrioventricular nodal re-entry tachycardia which most likely caused her palpitation. Successful ablation of the slow pathway was performed. A single chamber defibrillator was implanted for prevention of sudden cardiac death from HCM. FV pathway had never been demonstrated to be the key component of re-entrant tachycardia due to its short distance and considered to be benign.[1] Its pre-excitation pattern could mimic anteroseptal or mid-septal pathway and lead to the unnecessary risk of complete heart block with an attempted catheter ablation. Danon disease is an X linked dominant lysosomal storage disease derived from the genetic defects in LAMP gene mutation with multiorgan involvement.[2 3] Pre-excitation is very common and risk for sudden cardiac death is high[3 4] in patients with Danon disease.

Krittapoom Akrawinthawong, Vineet Kumar

Cardiovascular Medicine, University of Alabama at Birmingham, Birmingham, Alabama, USA

Correspondence to Dr Krittapoom Akrawinthawong, Cardiovascular Medicine, University of Alabama at Birmingham, Birmingham, AL 35233, USA; krittapoom.a@gmail.com

Contributors KA and VK wrote and revised the manuscript.

Funding The authors have not declared a specific grant for this research from any funding agency in the public, commercial or not-for-profit sectors.

Competing interests None declared.

Patient consent for publication Not required.

Provenance and peer review Not commissioned; externally peer reviewed.

To cite Akrawinthawong K, Kumar V. *Heart Asia* 2019;**11**:e011174.

Heart Asia 2019;**11**:e011174. doi:10.1136/heartasia-2018-011174

REFERENCES

1. Rohrhoff NJ, Finne HA, Rodriguez Y. A sailor's dilemma: a case of preexcitation via a fasciculoventricular pathway. *HeartRhythm Case Rep* 2017;3:364–7.
2. D'souza RS, Mestroni L, Taylor MRG. Danon disease for the cardiologist: case report and review of the literature. *J Community Hosp Intern Med Perspect* 2017;7:107–14.
3. D'souza RS, Levandowski C, Slavov D, *et al*. Danon disease: clinical features, evaluation, and management. *Circ Heart Fail* 2014;7:843–9.
4. Sternick EB, Oliva A, Gerken LM, *et al*. Clinical, electrocardiographic, and electrophysiologic characteristics of patients with a fasciculoventricular pathway: the role of PRKAG2 mutation. *Heart Rhythm* 2011;8:58–64.