Multiple fistula and abnormal vascular plexus

CASE

A 50-year-old female was admitted to the hospital for the preoperative evaluation. She complained of mild dyspnoea on exertion for years. Cardiovascular examination was unremarkable. Transthoracic echocardiography revealed abnormal continuous flow at the anterior side of proximal descending aorta (figure 1A, arrow). A CT angiography using 128-multidetector computed tomography (MDCT) was performed to evaluate the abnormal vascular network, and it showed a complex vascular plexus which was communicating with the right coronary artery (RCA), left internal mammary artery (IMA) and bronchial artery (figure 1B). Right coronary angiography showed a hyperplastic conus branch which was draining directly into pulmonary artery (PA) (figure 1C). Left internal mammary angiography revealed a vascular plexus shaped like a bunch of grapes which communicated with the PA (figure 1D). Bronchial artery was also hyperplastic and drained into pulmonary artery and bronchial vein (figure 1E).

We believe that the three-dimensional images of MDCT as compared with the two-dimensional images of conventional angiography provide better visualisation of the vascular abnormality and provide better spatial information on the vascular abnormality with respect to the surrounding cardiac structures. Therefore, CT angiography is very helpful for determining treatment modality and making surgical plans.

Jong-Seon Park, Geu-Ru Hong, Sang-Hee Lee

Correspondence to Professor Jong-Seon Park, Yeungnam University Hospital, #317-1 Daemyung-dong Nam-gu Daegu 705-717, Republic of Korea; pjs@med.yu.ac.kr

Competing interests None.

Provenance and peer review Not commissioned; externally peer reviewed.

Heart Asia 2010:19. doi:10.1136/ha.2009.000992

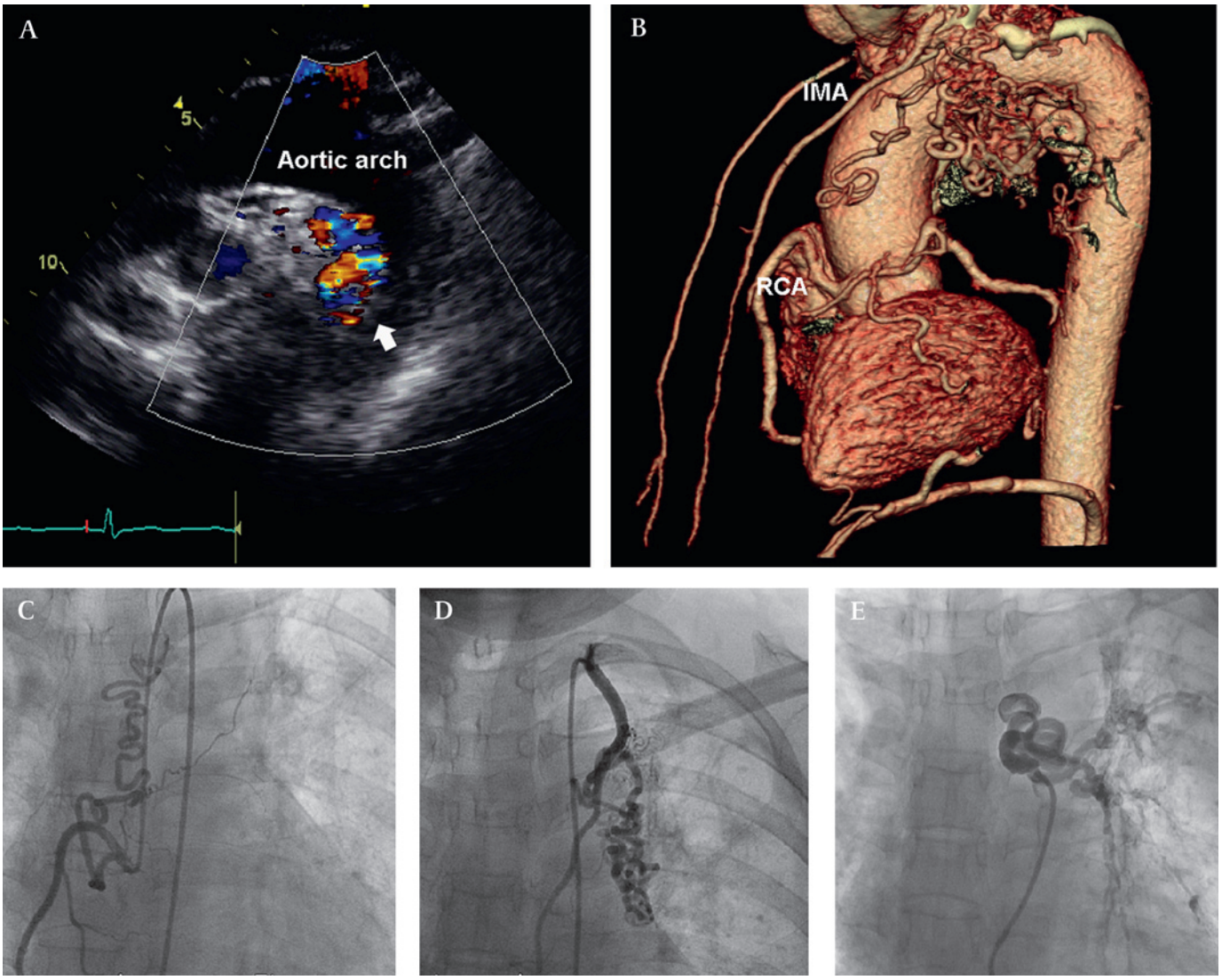

Figure 1 Transthoracic echocardiography, CT angiography and right coronary angiography of the patient.