Tail of a pig: a small trick

CASE REPORT

A 48-year-old woman presented with recurrent syncope. She had a modified radical mastectomy for breast cancer on the right side. ECG revealed a complete heart block. Permanent pacing was planned from the left side. We saw an unusual course of the pacing lead (figure 1 and online supplementary video). A venogram showed the left-sided superior vena cava (SVC) draining into the right atrium. It was difficult to negotiate the lead from the right atrium to the right ventricle. We made a 360° loop of the stylet like the tail of a pig. The pacing lead then entered the right ventricle easily. The patient has been asymptomatic for the last 1 year.

DISCUSSION

A persistent left superior vena cava (PLSVC) is present in 0.3–0.5% of the general population and in 3–10% patients with congenital heart disease.[1] The diagnosis is revealed unexpectedly during the implantation of a pacemaker or an intracardiac defibrillator. The caudal portion of the right superior cardinal vein forms the right-sided SVC while the portion of the left superior cardinal vein caudal to the innominate vein normally regresses to become the 'ligament of Marshall'. If this normal regression fails to occur, it results in a PLSVC. It may be associated with an absent left brachiocephalic vein (65%), or an absent right SVC (10–18%).

In 80–90% of individuals, the PLSVC drains into the right atrium via the coronary sinus. In the remaining cases, it may drain in the left atrium. The ontogenetic development of the sinus node, the atrioventricular node and the His bundle might be influenced by the lack of regression of the left cardinal vein.

Transthoracic echocardiography reveals a dilated coronary sinus and diagnosis can be confirmed by the use of saline contrast ('bubble study') echocardiography. It can have a variety of associated cardiac anomalies such as atrial septal defect, bicuspid aortic valve, coarctation of aorta, coronary sinus ostial atresia and cor triatriatum. Some technical manoeuvres may facilitate the pacing procedure.[2]

A small volume of contrast can be injected into the pacing sheath to visualise the coronary sinus opening into the right atrium and the right ventricle. Fluoroscopy in oblique views can be helpful in guiding the atrial lead into the anteriorly placed atrial appendage. The dilator and the sheath should be introduced with special care because a sharp turn from the subclavian vein to the PLSVC may invite laceration of the vein or kinking of the sheath.

An active-fixation pacing lead is preferable because of the risk of displacement. We found that making a nearly 360° clockwise loop of the stylet like the tail of a pig allowed passage through the tricuspid valve easily. A J-wire is of no use as it prohibits lead placement in patients with LSVC. Retention of a large atrial loop minimises displacement of the lead by avoiding sharp angulations. A PLSVC can complicate a permanent pacemaker and intracardiac defibrillator implantation with arrhythmia, cardiogenic shock, cardiac tamponade and coronary sinus thrombosis.

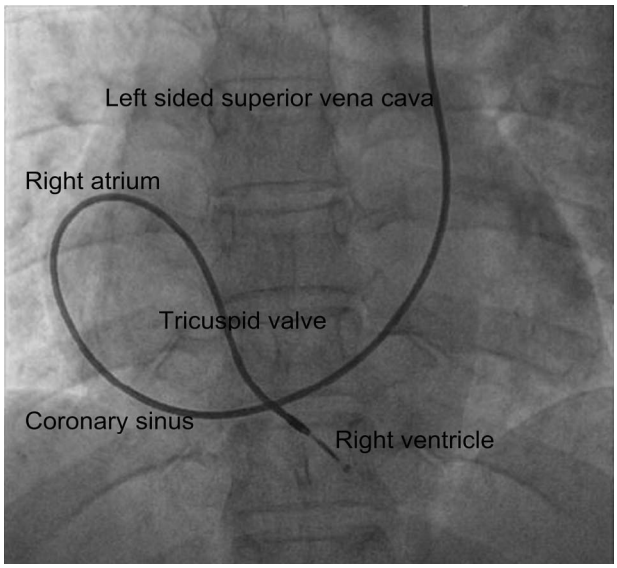

Figure 1 Pacing lead course—left-sided superior vena cava, coronary sinus, right atrium, tricuspid valve, right ventricle.

Goutam Datta

Department of Cardiology, Burdwan Medical College, Calcutta, India

Correspondence to Dr Goutam Datta, Department of Cardiology, Burdwan Medical College, P3 Lake Gardens Govt. Housing, 48/4 Sultan Alam Road, Calcutta 33, India; goutamdattadn@yahoo.in

Contributors GD is the sole author and contributor.

Funding None.

Competing interests None.

Patient consent Obtained.

Provenance and peer review Not commissioned; internally peer reviewed.

▶ An additional supplementary video is published online only. To view this file please visit the journal online (http://dx.doi.org/10.1136/heartasia-2012-010190).

To cite Datta G. *Heart Asia* Published Online First: 7 December 2012 doi:10.1136/heartasia-2012-010190

Heart Asia 2012;**0**:170. doi:10.1136/heartasia-2012-010190

REFERENCES

1 Rodríguez-Fernández JA, Almazán-Soo A. Pacemaker lead implant via the persistent left superior vena cava. *Arch Cardiol Mex* 2005;75(Suppl 3):S3-106–12.
2 Westerman GR, Baker J, Dungan WT, *et al*. Approach and report of dual-chambered lead placement: permanent pacing through a persistent left superior vena cava. *Ann Thorac Surg* 1985;39:174–6.

Heart Asia: first published as 10.1136/heartasia-2012-010190 on 10 December 2012. Downloaded from http://heartasia.bmj.com/ on April 20, 2024 by guest. Protected by copyright.