Pericardial liposarcoma

A 70-year-old Indian woman with hypertension presented with acute breathlessness. The chest radiograph revealed gross cardiomegaly (figure 1), ECG had fixed T wave inversion laterally and troponin-T was elevated (3.5 ng/ml). Echocardiography showed normal left ventricular (LV) size and good function; however, there was a large intrapericardial mass without effusion.

Cardiac catheterisation with left ventriculography demonstrated smooth coronary arteries significantly distant from the heart and infiltration of the LV apex (online supplementary video 1). Cardiac MRI revealed extensive mediastinal and intrapericardial lipomatosis (figure 2; arrows and arrowheads, respectively) with the heart 'floating' within the pericardial fat (online supplementary video 2). There was tethering and akinesis of the LV apex, LV base and anterolateral wall, together with interatrial septal infiltration. The patient was diagnosed as having pericardial liposarcoma but she declined surgical excision despite repeated hospital admissions with acute pulmonary oedema.

Pericardial liposarcomas are extremely rare[1] although liposarcomas are among the most common soft-tissue tumours in adults. There have been <20 cases of pericardial liposarcomas reported on PubMed since 1973. The treatment of choice is surgical excision. Adjuvant radiotherapy is used in cases of poorly differentiated tumours, incomplete resection or inoperability, since liposarcomas are considered to be insensitive to chemotherapy.[2]

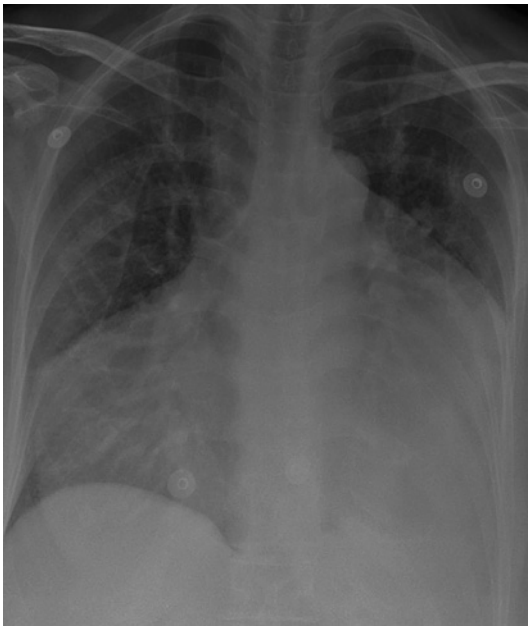

Figure 1 Chest radiograph: gross cardiomegaly.

Figure 2 Cardiac MRI: extensive mediastinal and intrapericardial lipomatosis (arrows and arrowheads respectively).

Rina Ariga, Rami Harb, James C Moon

Correspondence to Dr Rina Ariga; rina.ariga@gmail.com

► Additional videos are published online only. To view these files please visit the journal online (http://heartasia.bmj.com).

Contributors RA wrote the article and managed the patient in the clinic; RH managed the patient in the ward and performed the angiogram; JCM performed the MRI scan of the patient.

Competing interests None.

Patient consent Obtained.

Provenance and peer review Not commissioned; internally peer reviewed.

Heart Asia 2012;**4**:31. doi:10.1136/heartasia-2011-010053

REFERENCES

1. **Wang J,** Wei Z, Liu H, *et al*. Primary pleomorphic liposarcoma of pericardium. *Interact Cardiovasc Thorac Surg* 2010;**11**:325–7.
2. **Llombart-Cussac A,** Pivot X, Contesso G, *et al*. Adjuvant chemotherapy for primary cardiac sarcomas: the IGR experience. *Br J Cancer* 1998;**78**:1624–8.

Heart Asia: first published as 10.1136/heartasia-2011-010053 on 6 March 2012. Downloaded from http://heartasia.bmj.com/ on April 16, 2024 by guest. Protected by copyright.