

Syncope in young

A 34-year-old woman presented with recurrent syncope.

Electrocardiogram revealed complete heart block. Dual-chamber pacemaker was implanted. Two months later she returned with recurrent syncope. Pacemaker was functioning normally, but she had repeated episodes of ventricular tachycardia (VT). Her echocardiography, chest X-ray and biochemical parameters were within normal limits.

She had lupus pernio in her nose this time (figure 1). Non-caseating granuloma was found in skin biopsy and diagnosis of sarcoid was made (figure 2). MRI was not possible because of pacemaker. There were small bilateral hilar lymphadenopathy in CT scan of chest without any parenchymal infiltration. Patchy involvement of septum and left ventricular free wall were seen in Thallium201 scan.¹ She was put on oral corticosteroid and dual-chamber implantable cardioverter-defibrillator (ICD) was implanted to prevent sudden cardiac death. Her VT load has decreased in follow-up, and she did not receive a single shock. Eventually, her pacemaker dependency has also decreased. In the USA, 13–50% of all sarcoidosis deaths have been attributed to cardiac involvement; in Japan, up to 85% of all deaths have been related to heart involvement. Though left ventricular free wall is the most common location, interventricu-

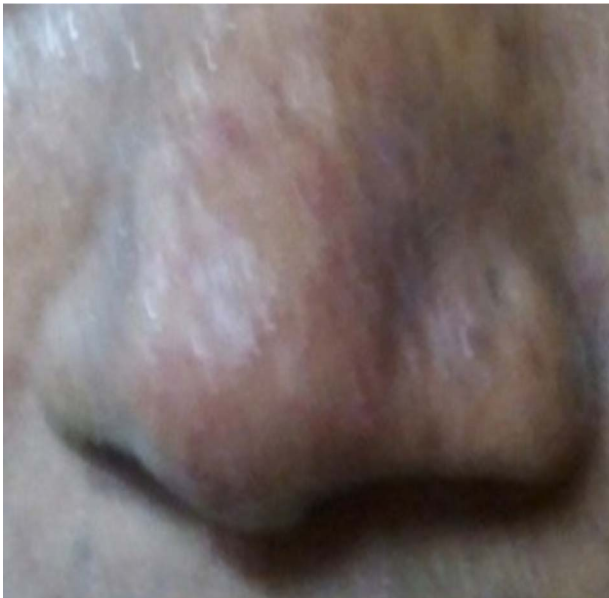

Figure 1 Lupus pernio.

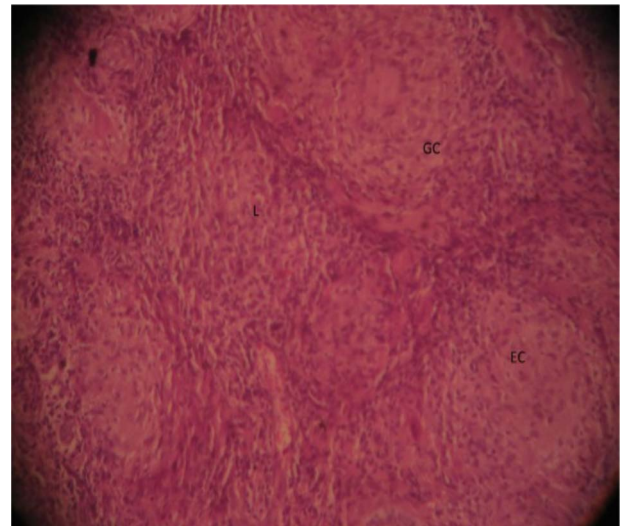


Figure 2 Sarcoid granuloma.

lar septum is frequently affected in sarcoidosis. The focal granuloma interrupts the cardiac conduction system in one-third of symptomatic patients.² It may manifest as various types of atrio-ventricular conduction defects, bundle branch blocks, different ventricular and supraventricular arrhythmias and sudden cardiac deaths. The reported success rate of endomyocardial biopsy for diagnosis is generally 25%. Non-caseating granulomas, epithelioid cells, multinucleated giant cells, asteroid bodies, Schaumann bodies could be seen in biopsy specimens.

Goutam Datta

Correspondence to Dr Goutam Datta, Department of Cardiology, Burdwan Medical College, P-3 Lake Gardens Govt. Housing, 48/4 Sultan Alam Road, Calcutta 33, India; goutamdattadn@yahoo.in

Competing interests None.

Patient consent Obtained.

Provenance and peer review Not commissioned; internally peer reviewed.



CrossMark

To cite Datta G. *Heart Asia* 2014;**6**:87.

Heart Asia 2014;**6**:87. doi:10.1136/heartasia-2014-010543

REFERENCES

- 1 Youssef G, Beanlands RS, Birnie DH, *et al*. Cardiac sarcoidosis: Applications of imaging in diagnosis and directing treatment. *Heart* 2011;**97**:2078–87.
- 2 Fawcett FJ, Goldberg MJ. Heart block resulting from myocardial sarcoidosis. *Br Heart J* 1974;**36**:220–3.